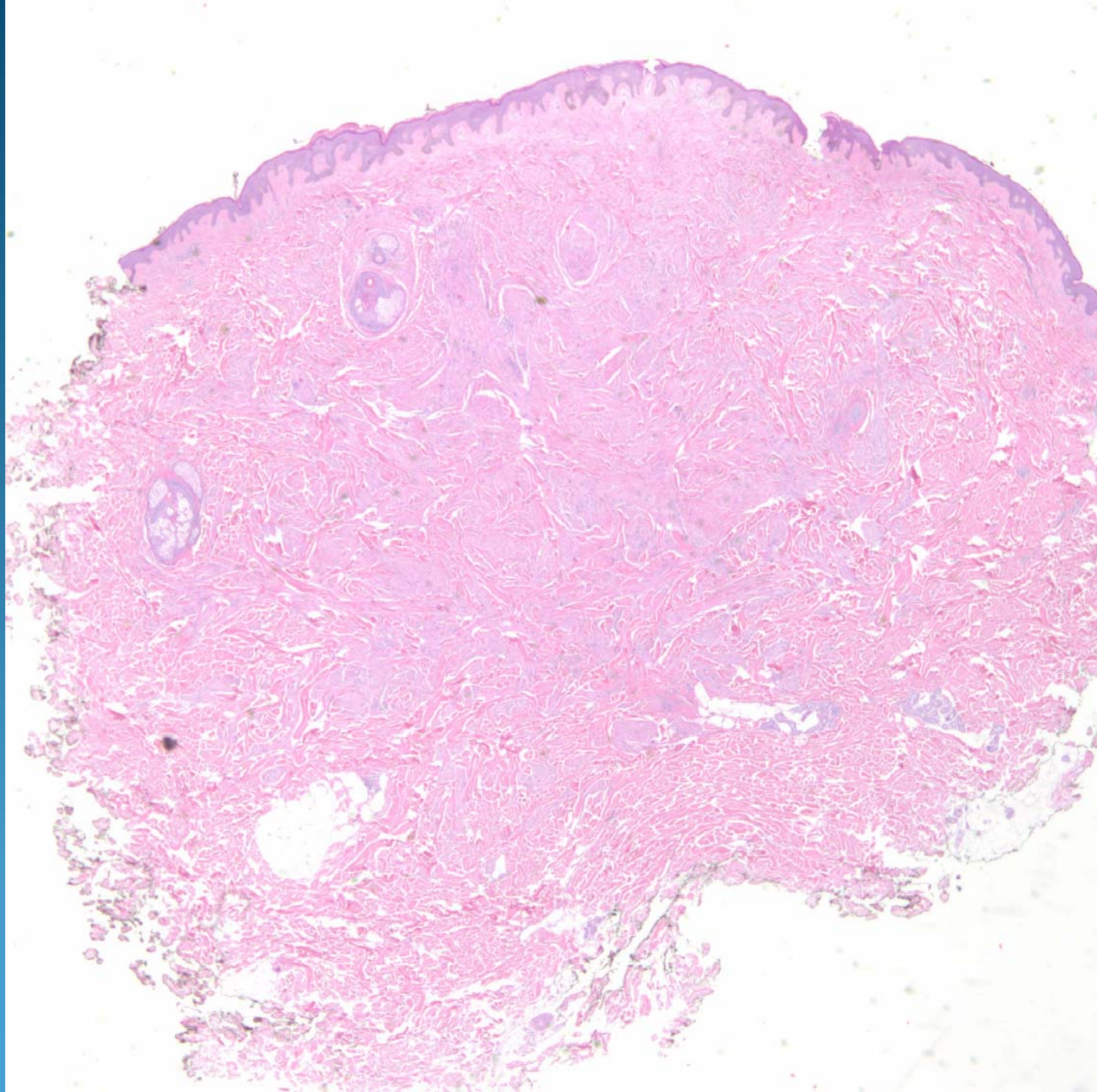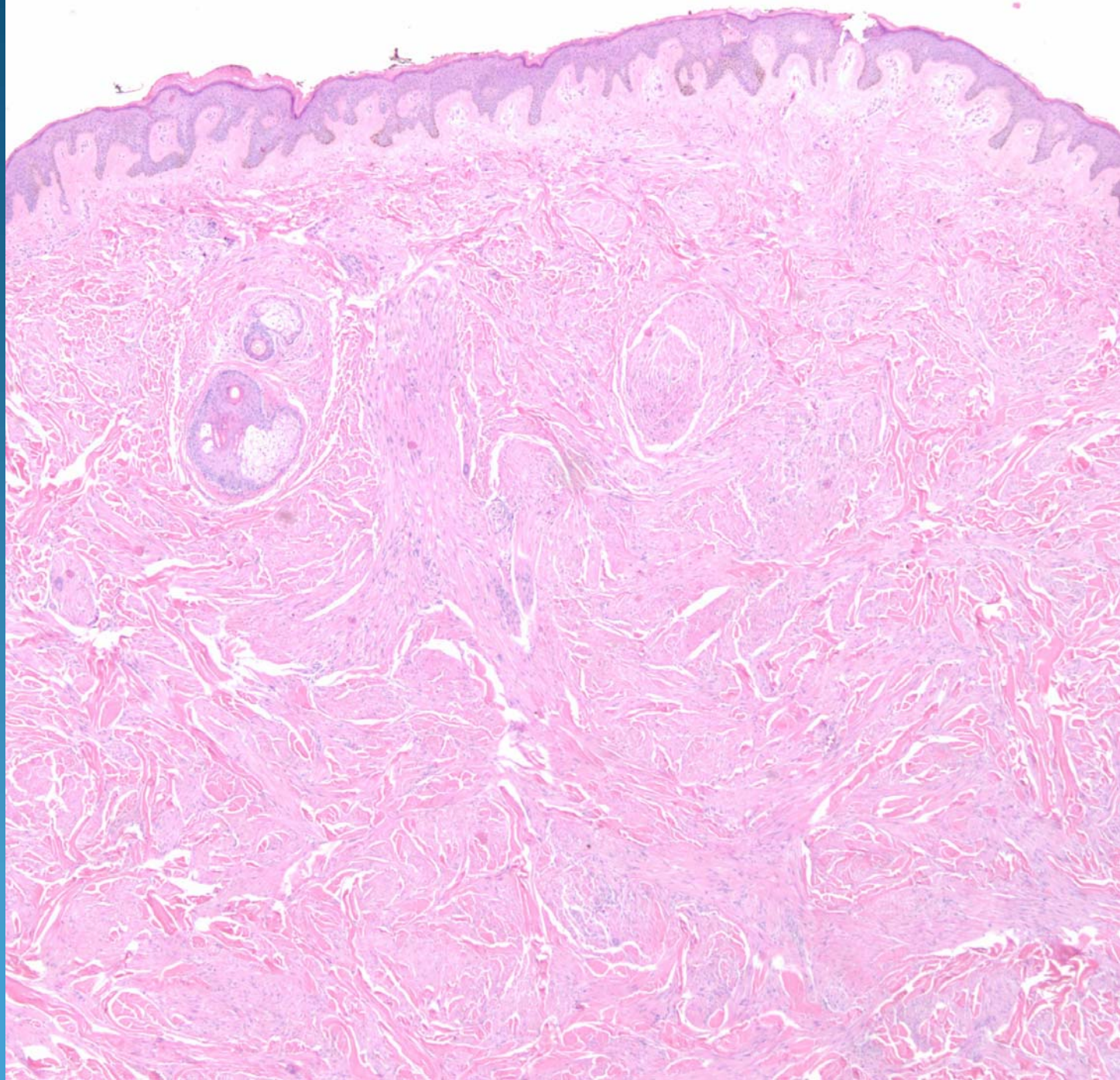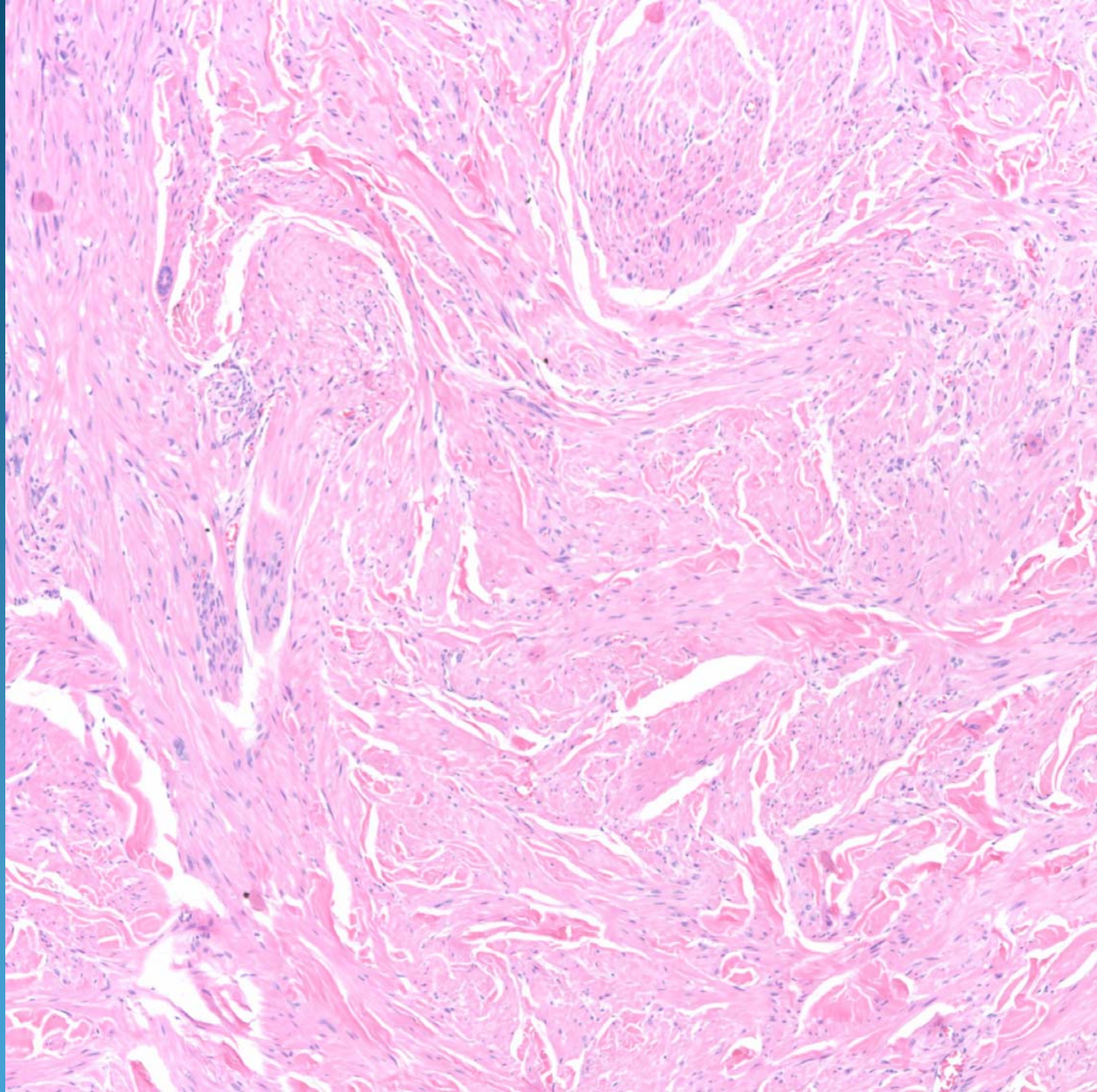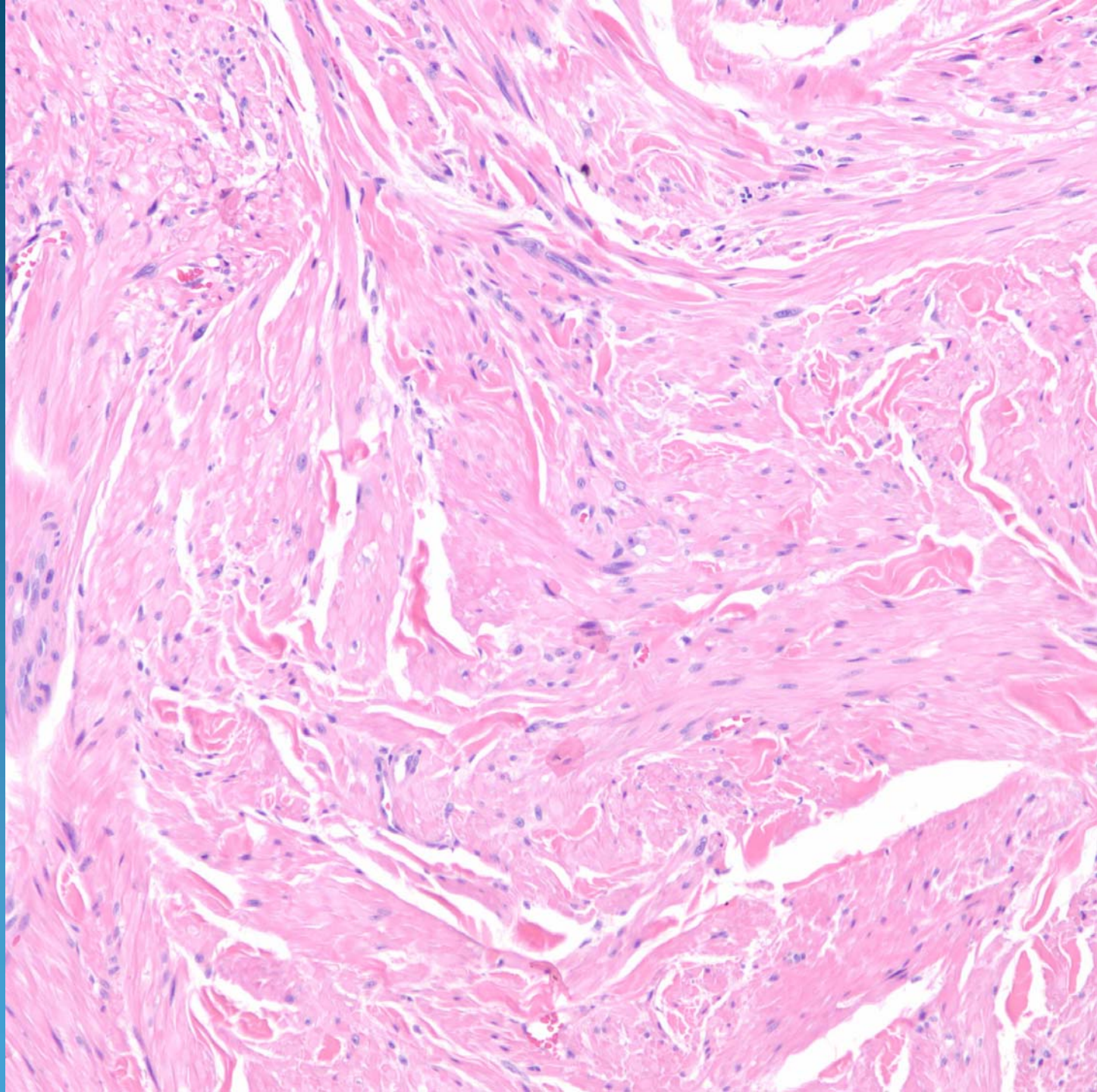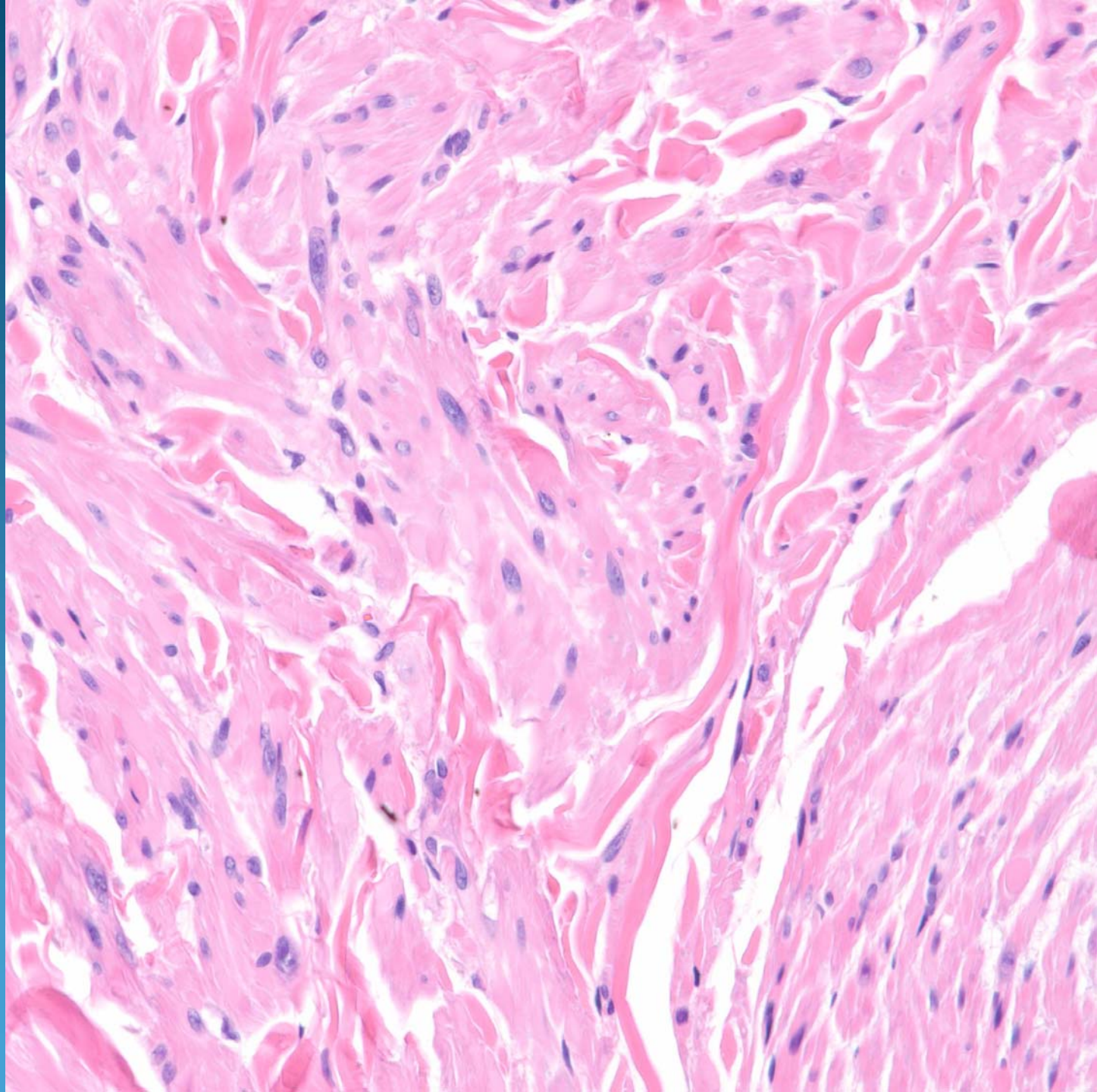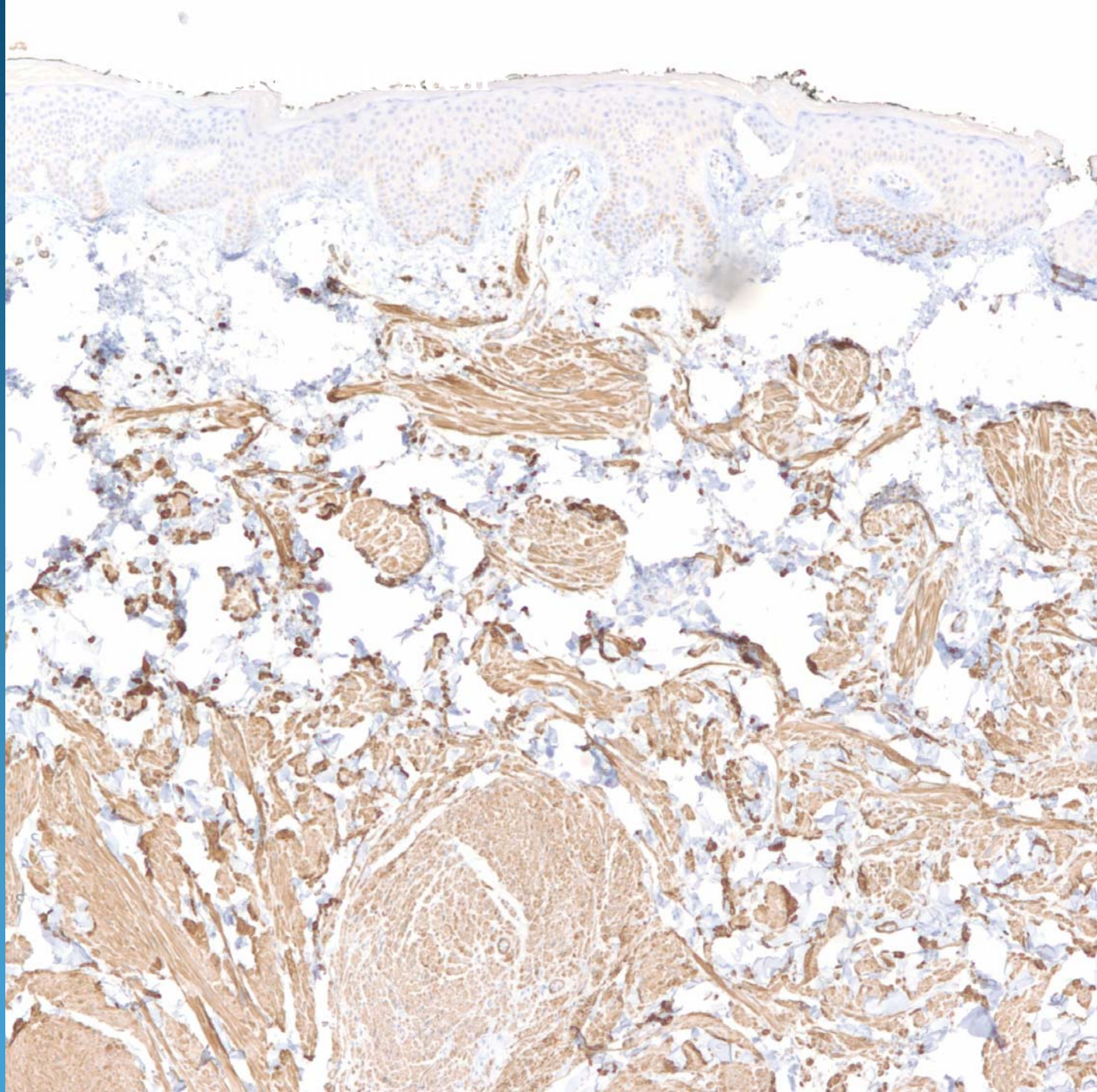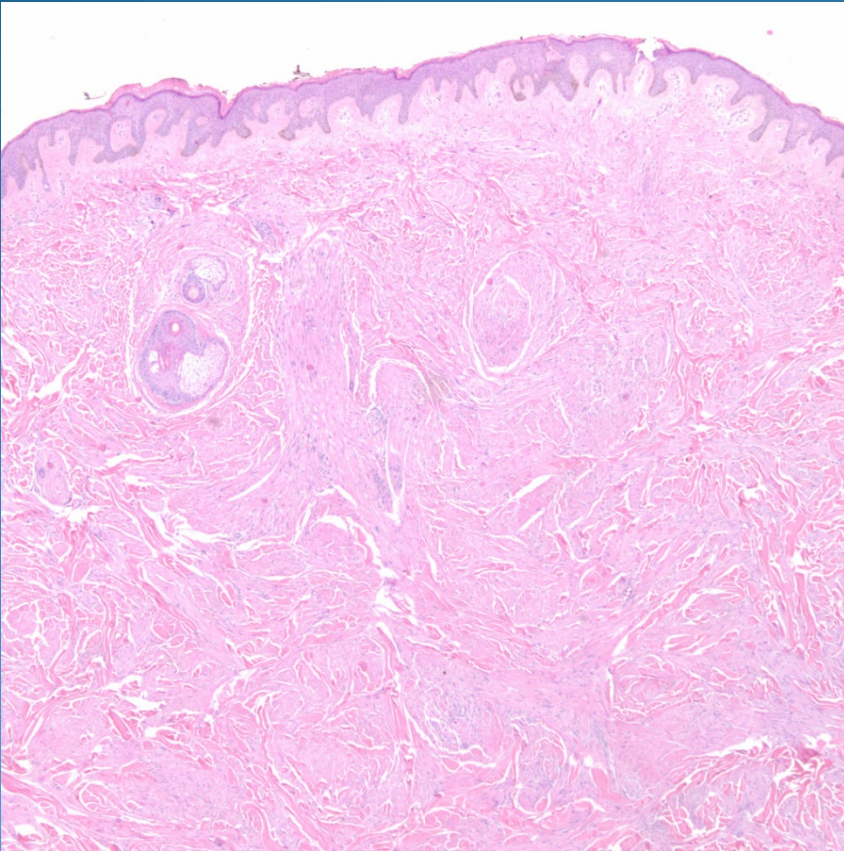


# Cutaneous Leiomyoma



# Pearls



- Partly circumscribed collection of bland spindle cells, arranged in intersecting fascicles
- May show perinuclear halos
- Minimal atypia or mitotic figures
- Superficial tumors usually arising from pilar arrector muscle
- May need IHC to confirm